Intense Pulsed Light as a Nonablative Approach to Photoaging

MITCHEL P. GOLDMAN, MD,* ROBERT A. WEISS, MD,† AND MARGARET A. WEISS, MD†

*La Jolla Spa MD, La Jolla, California; †Department of Dermatology, Johns Hopkins University School of Medicine and the Maryland Laser, Skin and Vein Institute, Baltimore, Maryland

BACKGROUND AND OBJECTIVE. **To describe the introduction and use of intense pulsed light (IPL) to treat vascular and pigmented lesions comprising photorejuvenation and its use in photodynamic therapy.**

METHODS. **Review of the medical literature and the authors' experience with IPL.**

RESULTS AND CONCLUSIONS. **IPL is an excellent treatment modality for vascular and pigmented manifestations of photoaging and can be combined with photodynamic therapy for the treatment of early forms of skin cancer.**

ROBERT WEISS, MD, HAS RECEIVED HONORARIA AS A SPEAKER FOR LUMENIS, PALOMAR, LASERSCOPE, CYNOSURE, AND THERMAGE. MITCHEL P. GOLDMAN IS A CONSULTANT FOR, RECEIVES HONORARIA FROM, PERFORMS RESEARCH FOR, AND HOLDS STOCK IN LUMENIS AND DUSA PHARMACEUTICALS.

ONE OF the most controversial light-based technologies, which had its birthplace in San Diego in 1992 and was cleared by the US Food and Drug Administration (FDA) in late 1995 as the Photoderm (ESC/Sharplan, Norwood, MA, USA; now Lumenis, Santa Clara, CA, USA), is noncoherent polychromatic filtered flashlamp intense pulsed light (IPL) source. It was initially launched and promoted as a radical improvement over existing methods for elimination of leg telangiectasia owing to pressure from venture capital groups that funded its development. Although the treatment of leg telangiectasia was possible, additional advantages recognized early on were IPL's ability as a specific modality to minimize the possibility of purpura common to pulsed dye lasers (PDLs) and the elimination of hair and lentigines. Continued use proved that the device was of far greater utility for other indications than leg telangiectasias.[1–10] The road to usability, reproducibility, and efficacy was a long one, with some clinical users and many "laser experts" dismissing the IPL as a harmful and useless form of technology. The term "photoburn" was commonly used. It is ironic that IPL is now considered the gold standard for treatment of vascular lesions in addition to the many signs of photoaging.[1–3,11,12] Testimony to the acceptance of IPL as a valid, efficacious technological breakthrough is evidenced by over 10 different manufacturers producing various forms of IPL, with the estimated sale of 10,000 IPL devices worldwide in the last 10 years.

The IPL device consists of a flashlamp housed in an optical treatment head with water-cooled reflecting mirrors. An internal filter overlying the flashlamp prevents wavelengths less than 500 nm from being emitted. Water surrounding the flashlamp prevents wavelengths greater than 900 nm from being emitted by many IPL devices. Optically coated quartz filters of various types (cutoff filters) are placed over the window of the optical treatment head or are imbedded into the quartz or sapphire light guides to eliminate wavelengths lower than the filter. Although some IPL devices have one or two cutoff filters, available cutoff filters are 515, 550, 560, 570, 590, 615, 645, 690, and 755 nm. Finally, to allow optimal transmission of light by decreasing the index refraction of light to the skin and promoting a "heat-sink" effect, filter crystals are often optically coupled to the skin with various thicknesses of a transparent water-based gel.

Although Lumenis is the largest and most well known of the IPL device manufacturers, other manufacturers now supply pulsed light devices (Table 1). Since virtually no peer-reviewed published data on these other devices exist, the subsequent discussion focuses primarily on the Lumenis technology. We do not imply that Lumenis systems are the only IPLs that are medically effective. It is our experience that many forms of IPL devices are effective, with advantages and disadvantages unique to each technology.

Wavelength

The working premise for IPL is that noncoherent, polychromatic light can be manipulated with filters to meet the requirements for selective photothermolysis—that for a broad range of wavelengths, the absorption coefficient of blood in the vessel was higher than that of the surrounding bloodless dermis. When filtered, the Lumenis IPL device is capable of emitting a broad bandwidth of light from 515 nm to approximately 1,200 nm. (Other IPLs have different wavelength outputs.) This bandwidth is

Address correspondence and reprint requests to: Mitchel P. Goldman, MD, Dermatology/Cosmetic Laser Associates of La Jolla, Inc., 7630 Fay Avenue, La Jolla, CA 92037, or e-mail: mgoldman@spa-md.com.

ISSN: 1076–0512 • Dermatol Surg 2005;31:1179–1187.

Table 1. Manufacturers and Brand Names of Intense Pulsed Light Devices

Manufacturer	*Brand Name*	*Output, nm*	*Spot Sizes, mm*	*Fluence (maximum)*
Lumenis	Photoderm VL/PL	515–1,200	4 × 8,	90 J/cm²
	Epilight	590–1,200	8 × 35, 10 × 45	
	Multilight HR	515–1,200		
	Vasculight HR	515–1,200 and 1,064 laser		
	Quantum SR	560–1,200		
	Quantum HR	560–1,200 and		
	Vasculight–SR	1,064 laser		90 J/cm²
	Lumenis One	515–1,200	20× 50	
Energis Technology	Energis Elite IPL	600–950	10 × 50	19 J/cm²
Danish Dermatologic Development A/S,	Ellipse	Wavelength 400–950	10 × 48 Footprint (spot size) Ø8	22 J/cm²
Medical Bio Care	OmniLight FPL	515–920		45 J
OptoGenesis	EpiCool–Platinum	525–1,100		60 J
Primary Tech	SpectraPulse	510–1,200		10–20 J
Syneron	Aurora DS	580–980		10–30 J/cm²
Palomar	Starlux Y	525–1,200		15 J
	G	500–670/870–1,400		30 J
Alderm	Prolite	550–900 20 × 25	10 × 20 and	10–50 J

modified by application of filters that exclude the lower wavelengths. Although the output is not uniform across this spectrum, it has been shown that with the Lumenis IPL, during a 10-millisecond pulse, relatively high doses of yellow light at 600 nm are emitted, with far less red and infrared, although output has been demonstrated beyond 1,000 nm (Figure 1).[4] Spectral outputs for other IPL systems are proprietary. The peak emission of the optical treatment head in the 600 nm region and other yellow wavelengths most likely facilitates selective absorption by bright red superficial vessels.

Selectivity is theoretically obtained for deoxyhemoglobulin throughout the 600 to 750 nm range. Although oxyhemoglobin is characterized by a very high absorption coefficient up to 630 nm, absorption drops at longer wavelengths but rises again to a broad peak in the near infrared in the 800 to 900 nm range (Figure 2). Deoxyhemoglobin is similar to oxyhemoglobin up to 600 nm, but absorption does not drop as fast as that of oxyhemoglobin at 600 to 750 nm. It has been shown that blue telangiectasias are only slightly more deoxygenated compared with red telangiectasias.[13] In addition, by treating a vessel with multiple pulsing, oxygenated hemoglobin is converted to deoxygenated hemoglobin during the first portion of the sequential pulsing.

Pulse Durations

Allowing proper thermal relaxation time between pulses theoretically prevents elevation of epidermal temperatures above 70°C and is an inherent advantage of "multiple

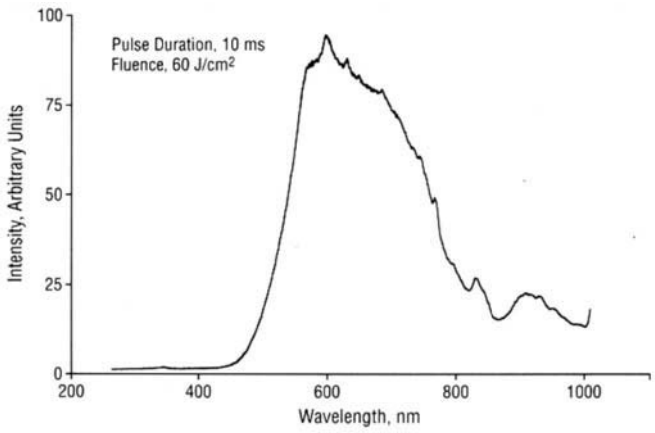

Figure 1. Emission spectrum of an intense pulsed light head with the 515 nm filter at 10-millisecond pulse duration. Peak output is shown by the line at 600 nm. Courtesy of Holger Lubatschowski, PhD, Laser Zentrum, Hannover, Germany.

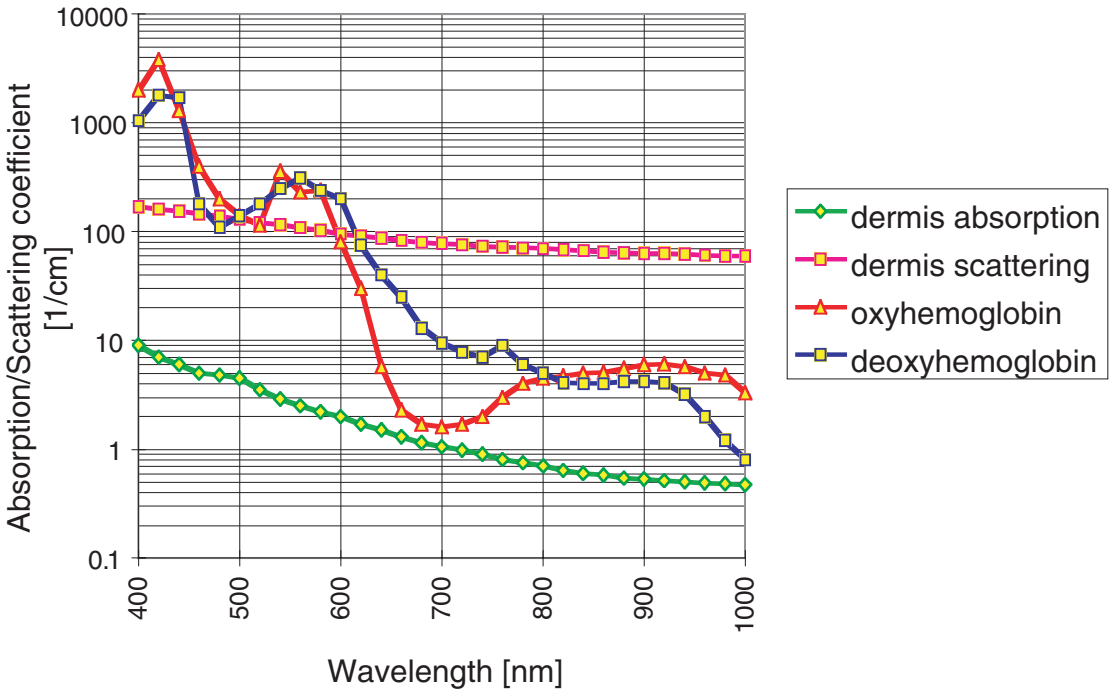

Figure 2. Absorption curve of hemoglobin in different states of oxygenation. Since collagen absorbs very little on its own, the primary components absorbing light are hemoglobin and melanin (melanin is not shown). There is a zone from 600 to 750 nm in which deoxyhemoglobin has preferential absorption. Courtesy of Lumemis; reproduced with permission from Goldman MP, Fitzpatrick RE. Cutaneous laser surgery: the art and science of selective photothermolysis. 2nd ed. St. Louis: Mosby; 1999.

sequential pulsing" of the IPL device. Thermal relaxation time is the amount of time it takes for the temperature of a tissue to decrease by a factor of $\varepsilon = 2.72$ as a result of heat conductivity. For a typical epidermal thickness of 100 microns, the thermal relaxation time is about 1 millisecond. For a typical vessel, 100 microns (0.1 mm), the thermal relaxation time is approximately 4 milliseconds; for a vessel of 300 microns (0.3 mm), the thermal relaxation time is approximately 10 milliseconds. Therefore, vessels greater than 0.3 mm cool more slowly than the epidermis with a single pulse. For larger vessels, however, multiple pulses may be advantageous, with delay times of 10 milliseconds or more between pulses for epidermal cooling. This delay time must be increased with larger vessels because thermal diffusion across a larger vessel elongates the thermal relaxation time. Multiple sequential pulsing with delay times permits successive heating of targeted vessel(s) with adequate cooling time for the epidermis and surrounding structures.

These theoretical considerations imply that (1) vessels smaller than 0.3 mm should theoretically require only a single pulse, although a double pulse should have no adverse effect on treatment; (2) pulses should be spaced 10 milliseconds or longer to accommodate normal epidermal thermal relaxation times; a 20- to 30-millisecond thermal relaxation time is recommended for patients with skin types that are highly reactive to thermal damage, such as Asian skin; (3) bright red lesions (oxyhemoglobulin) are better treated with 515 to 590 nm filters; (4) blue lesions (deoxyhemoglobulin) should be treated with 590 nm or higher filters; and (5) darker skin types should be treated with the highest filter available, double pulses, accompanied by increasing delay times between pulses (typically 20–40 milliseconds) to allow for increased skin thermal relaxation times

The treatment of darker-skinned individuals (types IV–VI) and/or patients with hyperreactive melanocytes becomes of increasing concern when performing photoepilation. In these cases, the 755 nm filter is used primarily with delay times between pulses from 50 to 100 milliseconds to allow plenty of time for the skin to cool down, avoiding thermal damage.

Concepts of Multiple Pulsing

The newest concepts for IPL and what has most contributed to the success of the technique are the ability to elongate pulse durations for larger vessels, shorten pulse durations for smaller vessels, and use these in a variety of combinations of synchronized short and long pulse widths.[14] For a small vessel (0.3 mm), heat distribution is assumed to occur instantaneously.[15] For a larger vessel, this cannot be assumed because more time is required to have heat pass from just inside the superficial vessel wall

through the vessel to the deeper wall. Additional cooling time is required to release the accumulated heat from the core to the vessel surface. These principles were demonstrated using double-pulse experiments with the 585 nm yellow dye laser in which larger vessels of port-wine stains (greater than 0.1 mm) absorbed greater energy fluences before reaching purpura after double pulses spaced 3 to 10 milliseconds apart.[16] In another study using pulsed laser irradiation at 585 nm, pulse durations were chosen between short pulse (0.45 milliseconds) and long pulse (10 milliseconds).[17] The results demonstrated that long-duration pulses caused coagulation of the larger-diameter vessels, whereas small-caliber vessels and capillaries showed resistance to photothermolysis at these parameters. This concept has been termed *photokinetic selectivity*.

Applying this concept to IPL, we found that increasing pulse durations up to 12 milliseconds causes larger vessels (0.5 mm or greater) to undergo more effective clinical photothermal coagulation while sparing the epidermis.[6] Obeying the principles of thermokinetic selectivity using IPL, the smaller overlying vessels in the papillary dermis do not absorb efficiently at longer pulse durations, causing less epidermal heating.

Treatment of Photoaging with IPL

Facial Telangiectasia

The treatment of facial telangiectasia is the foundation of treatment of photoaging by IPL. The clinical observation was made following treatment of facial telangiectasia that skin texture became smoother. This observation was made by the authors treating patients from 1995 to 1997. The parameters for IPL of facial telangiectasia with the Lumenis Vasculite and Quantum IPLs include a double pulse of approximately 2.4- to 4-millisecond duration with a 550 nm filter in light skin and 570 nm filter in darker-skinned patients. Typical delay times are 10 milliseconds in light skin and 20 to 40 milliseconds in dark and/or Asian skin. The fluences required are typically between 28 and 35 J/cm^2. Higher fluences are used when the second pulse duration is greater than 4.0 milliseconds so that a double pulse of 3.0 milliseconds and 6.0 milliseconds usually requires a fluence of 40 to 45 J/cm^2 to effectively treat a larger facial vessel (up to 1 mm diameter). The advantage of the IPL over the PDL is that with the large spot size, an entire cheek of telangiectatic matting can be treated with less than a dozen pulses in less than 5 minutes (Figure 3). In

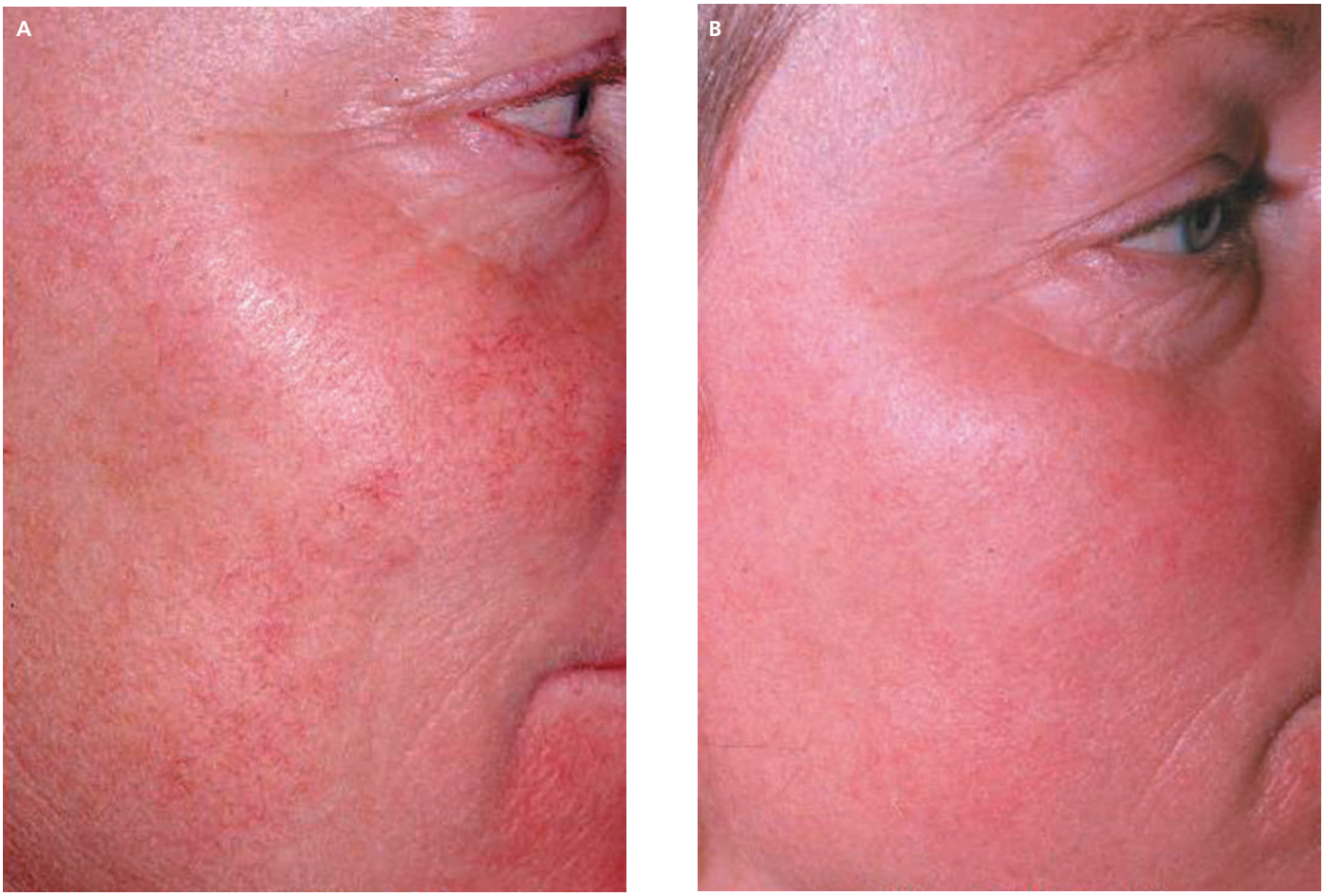

Figure 3. (A) Patient with rosacea; the entire cheek is treated with 30 pulses. (B) Results after three treatments spaced 1 month apart.

addition, there is little, if any, purpura. For larger, more purple telangiectasias typically seen on the nasal alae or for venous lakes or adult port-wine stains, the same settings may be employed as for small vessels of the leg, that is, a short pulse followed by a long pulse.

Poikiloderma of Civatte

This photoaging process consists of an erythematous, pigmented, and finely wrinkled appearance that occurs in sun-exposed areas, mostly on the neck, forehead, and upper chest. For areas of poikiloderma on the neck and lower cheeks consisting of pigmentation and capillary matting, the IPL device is ideal with the use of a 515 nm filter, which allows absorption both by melanin and hemoglobin simultaneously (Figure 4).[1] For patients with more dyspigmentation, one begins with higher filters, such as the 550 or 560 nm filter, to prevent too much epidermal absorption, which would result in crusting and swelling, lasting for several days. Additional treatments with the IPL may be performed with a 550, 560, or 570 nm filter to treat the vascular component of poikiloderma.

Photorejuvenation

The overall appearance of aging skin is primarily related to the quantitative effects of sun exposure with resultant ultraviolet damage of structural components, such as collagen and elastic fibers. The appearance, however, is also affected by genetic factors, intrinsic factors, disease processes such as rosacea, and the overall loss of cutaneous elasticity associated with age. With excessive sun exposure, visible signs of aging have become more evident in younger individuals. Photorejuvenation has been described as a dynamic nonablative process involving the use of the IPL to reduce mottled pigmentation and telangiectasias and smooth the textural surface of the skin.[18,19] The treatment is generally administered in a series of three to six procedures in 3- to 4-week intervals. The entire face is treated, rather than a limited affected area, and the patient may return to all activities immediately. Marketing has made the public and medical community aware of these changes through various unsuccessfully applied for service trademarks, such as Photofacial, Fotofacial, and Facialite. An example of photorejuvenation of photoaging is shown in Figure 5.

Zelickson and Kist demonstrated that IPL treatment results in an 18% increase in collagen type I transcripts, whereas PDL treatment results in a 23% increase in collagen type I transcripts.[20,21] This may explain the improvement in fine wrinkling with photorejuvenation. A further investigation demonstrated that collagen types I and III, elastin, and collagenase increased in 85 to 100% of patients and procollagen increased in 50 to 70% of patients.

Hernandez-Perez and Ibiett evaluated the histologic effects of five IPL treatments with 570 to 645 nm, 2.4 to 6.0 milliseconds, 20-millisecond delay, and 25 to 42 J/cm^2.[22] They showed epidermal thickening of 100 to 300 µm, better cellular polarity, a decrease in horny plugs, new rete ridge formation, decreased elastosis, and dermal neocollagen formation.

However, Prieto and colleagues, in a histologic study in patients with rosacea, did not see evidence of changes in

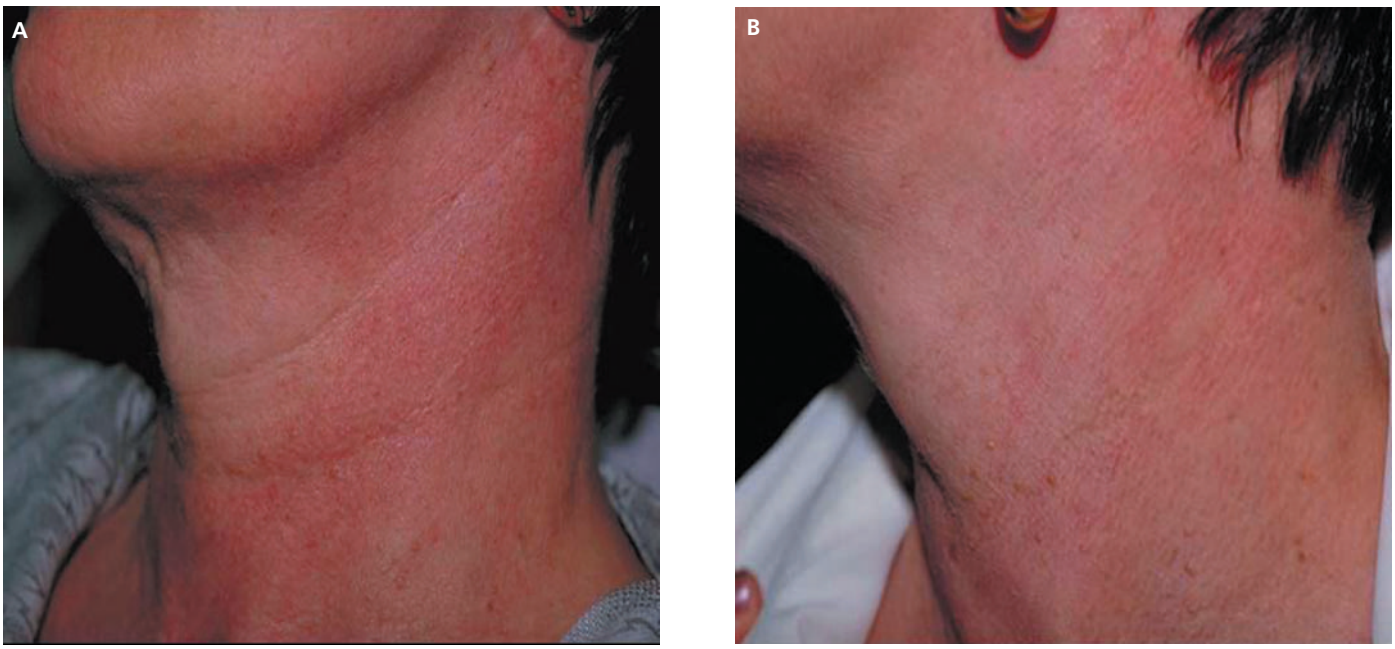

Figure 4. Treatment of poikiloderma of the neck. Initial treatment of single 3-millisecond pulse, 25 J/cm^2, 515 nm filter shows clearance in the area of two test pulses.

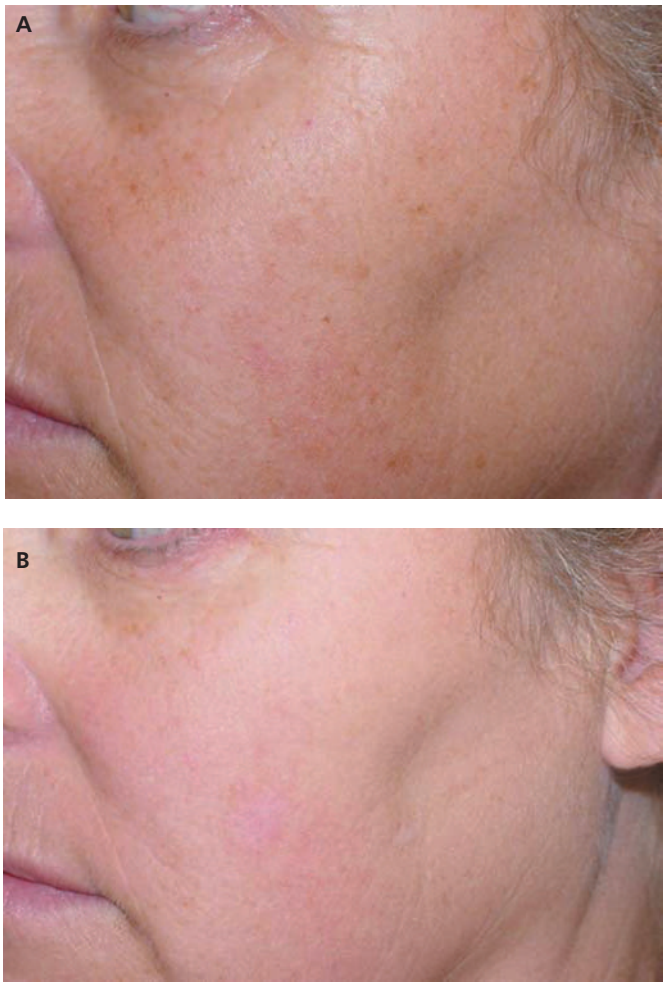

Figure 5. Photorejuvenation (A) before and (B) after three treatments. Excellent reduction in the photoaging components of mottled pigmentation, telangiectasias, and smoothing of the textural surface of the skin.

collagen, elastic, or reticular fibers but did note coagulated *Demodex*, which recurred after 3 months.[23] They treated patients at the following parameters: 560 nm, 2.4 to 4.2 milliseconds, 15-millisecond delay, and 28 to 36 J/cm^2, five times every month.

Negeshi and colleagues treated 73 patients in five sessions with either the Quantum IPL or the original IPL every 3 to 4 weeks at the following settings: 560 nm, 2.8 to 6.0 milliseconds, 20- to 40-millisecond delay, and 23 to 27 J/cm^2.[24,25] Eighty percent of her Japanese patients had greater than 60% improvement in pigmentation and erythema with smoother skin. The Quantum IPL has an integrated skin cooling crystal that cools the epidermis to 40°C during IPL versus 65°C without cooling.

The treatment of freckling is also improved with IPL photorejuvenation. Huang and colleagues used 550 to 590 nm filters with 25 to 35 J/cm^2, 4-millisecond single or double pulse, and 20- to 40-millisecond delay time in one to three treatments (mean 1.4) at 4-week intervals.[26] Their end point consisted of graying or perilesional erythema, and 91.7% of patients were extremely or very satisfied with treatment. Kawada and colleagues also treated freckling and lentigines in Asian skin.[27] They used a Quantum IPL at the following parameters: 560 nm, 20 to 24 J/cm^2, 2.6 to 5.0 milliseconds, and 20-millisecond delay in three to five treatments at 2- to 3-week intervals. No adverse effects were seen, and the patients reported that small patches and ephelides responded best (48% > 50% improvement; 20% > 75% improvement).

Weiss and colleagues evaluated 80 of their initial patients treated for vascular lesions to determine if "photorejuvenation" also occurred.[28] Images from three subsequent visits, including one follow-up at 4 years, were graded. There was an 80% improvement in pigmentation, telangiectasia, and skin texture. Hypopigmentation lasting for 1 year occurred in 2.5%, temporary mild crusting in 19%, erythema for more than 4 hours in 15%, hypo- or hyperpigmentation in 5%, and rectangular footprinting in 5%.

In a recent study, 49 subjects with varying degrees of photodamage were treated with a series of four or more full-face treatments at 3-week intervals using IPL (Vasculight IPL, Lumenis).[2] Fluences varied from 30 to 50 J/cm^2, with typical settings of double- or triple-pulse trains of 2.4 to 4.7 milliseconds with pulse delays of 10 to 60 milliseconds. Cutoff filters of 550 or 570 nm were used for all treatments. Photodamage, including wrinkling, skin coarseness, irregular pigmentation, pore size, and telangiectasias, was improved in more than 90% of the patients. Treatments involved IPL of the entire facial skin, except in males, who elected to avoid treatment of the beard area because of potential hair loss. In this study, 72% of subjects reported a 50% or greater improvement in skin smoothness and 44% reported a 75% or greater improvement. Minimal side effects were reported, with temporary discoloration consisting of a darkening of lentigines that resolved completely within 7 days. Two subjects reported a "downtime" of 1 and 3 days owing to moderate to severe swelling.

The use of IPL with a thermoelectrically chilled crystal delivery system (Quantum SR) on 20 patients for photorejuvenation has also been evaluated.[29] These patients underwent three monthly IPL treatments on the face, neck, and/or anterior chest. A 560 nm cutoff filter was used with a double pulse of 2.4 and 6.0 milliseconds separated by a 15-millisecond delay time. Fluences ranged from 26 to 30 J/cm^2. Telangiectasia improved in 84% of patients, dyspigmentation in 78%, and skin texture in 78%. Side effects were minimal and consisted of localized edema in 50% for less than 8 hours and erythema lasting from 2 to 24 hours.

The dual-mode filtering IPL system, Ellipse Flex DDD (Danish Dermatologic Development, Hoersholm, Den-

mark), was evaluated in 20 women for facial photorejuvenation.[30] First, areas of telangiectasia were treated with a pulse duration of 14 to 30 milliseconds. A second pass was then made with a double pulse of 2.5 milliseconds with a 10-millisecond delay. Two types of filters were used: 530 to 750 nm at an energy of 11 to 17 J/cm^2 and 555 to 950 nm at a fluence of 13 to 19 J/cm^2. Both groups reported significant improvement in both telangiectasia and pigmentation without adverse sequelae.

Photodynamic Skin Rejuvenation

The combination of IPL and photodynamic therapy (PDT) sensitizers, such as 5-aminolevulinic acid (ALA) (Levulan, DUSA Pharmaceuticals, Wilmington, MA, USA), allows for new options in the treatment of severely photodamaged skin[31] and may offer a significant cosmetically beneficial alternative to photodynamic treatments with blue light for such conditions as actinic keratoses,[32] early skin cancers,[33] and cystic acne.[34]

We have termed this advanced technique *photodynamic skin rejuvenation* (PSR). The PSR application of PDT involves activation of a specific photosensitizing agent, 5-ALA, activated by conventional IPL. This process produces activated oxygen species within cells, thus resulting in their elimination or destruction. The topically active agent ALA is the precursor in the heme biosynthesis pathway of protoporphyrin 9, which facilitates cellular destruction. Exogenous administration of ALA, along with 410 nm continuous blue light, has been cleared by the FDA for the treatment of actinic keratosis and appears to have significant long-term efficiency.[35] However, in clinical practice, a variety of light sources have been used in PDT in an effort to reduce time and discomfort for patients and enhance the clinical and cosmetic outcome of the procedure. Alexiades-Armenakas and colleagues were the first to describe the use of 595 nm pulsed light with ALA to treat actinic keratoses.[36] The advantages over blue light therapy were a decrease in pain during treatment and post-treatment erythema and crusting.

Since 595 nm is not an optimal peak of absorption for ALA, a broader wavelength, such as that found with the IPL, should be even more efficacious in activating ALA. IPL treatments are under study for such enhanced benefits of PDT.[37] Short-duration PDT, using Levulan for 15 to 60 minutes coupled with a treatment of IPL, has shown significant benefit in the treatment of precancerous conditions, such as actinic keratoses, as well as actinically damaged skin. Additionally, early evidence shows a significant degree of cosmetic enhancement (Figure 6).

Other variations of the procedure under study involve single IPL treatments with higher fluences and longer application times, resulting in dramatic decreases in actinic damage in a single treatment with a relatively short duration of healing. Additionally, initial studies show promise in application of topical ALA and IPL skin treatments using photorejuvenation in conditions such as moderate to severe acne and rosacea. The mechanism for improvement in acne and rosacea is due to the enhanced absorption of ALA by sebaceous glands. This enhanced absorption, followed by photoactivation with IPL, damages the sebaceous gland, causing its involution. A decrease in the size and/or activity of the sebaceous gland then leads to an improvement in acne.

Adverse Reactions

In our experience with thousands of treatment sessions, there has been about a 2% incidence of scattered areas of crusting in areas of increased pigmentation. This typically

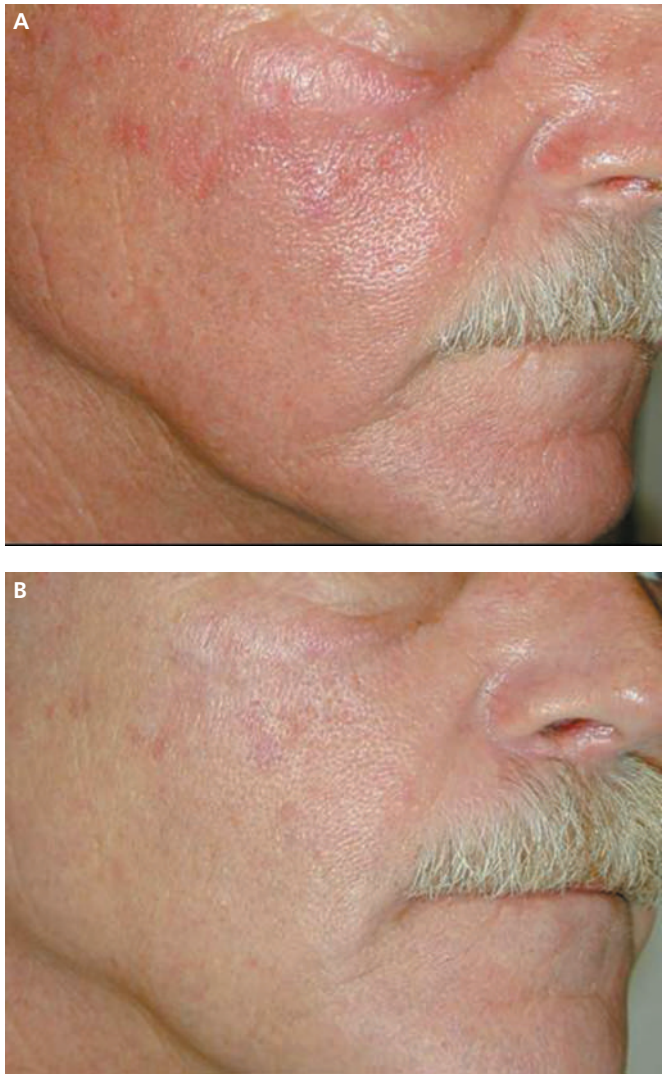

Figure 6. (A) Extensive photodamage and actinic keratosis in a 55-year-old man. (B) Six months after treatment with 5-aminolevulinic acid applied to the entire face and left on for 1 hour followed by intense pulsed light to the entire face with a 560 nm filter, 32 J/cm^2, and double pulse of 3.0 and 6.0 milliseconds with a 10-millisecond delay time.

heals within 7 days by peeling off. We accelerate this process by having the patients apply a moisturizer twice a day and/or undergo a treatment with microdermabrasion 1 to 2 days after IPL treatment. When there is no underlying pigmentation, crusting occurs primarily on curved body areas, such as the neck over the sternocleidomastoid muscle curvature. Purpura occurs in scattered, isolated pulses in about 4% of treatments. Purpura is more likely when the 515 nm filter is used or when the pulse durations are too short, such as coupling a 2.4-millisecond pulse duration with another 2.4-millisecond pulse duration. The purpura from IPL is different from typical short-pulse PDL purpura in that resolution occurs within 2 to 5 days as opposed to the 1- to 2-week purpura seen with PDL treatment.

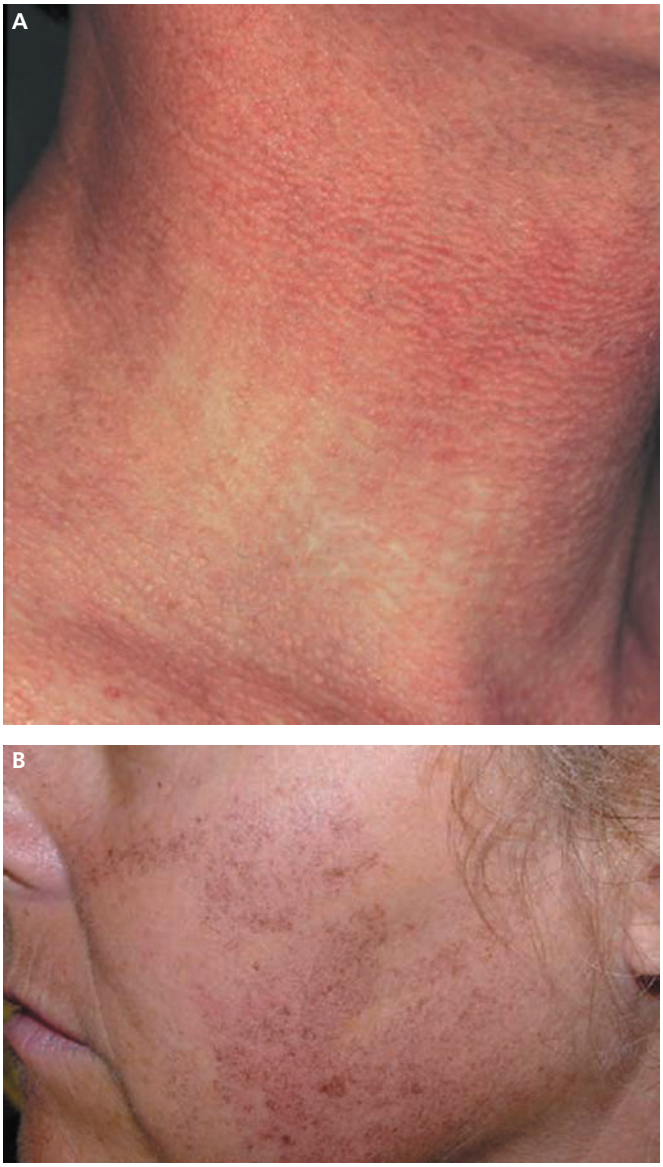

Figure 7. (A) Rectangular footprints owing to fluence too high for the pulse duration selected. (B) Crusting, a side effect that clears within several days to a week. This occurs only when an erythematous rectangular footprint is observed immediately post-treatment.

Other adverse effects of IPL include a stinging pain described as a brief grease splatter, electric shock, or rubber band snapping on the skin during treatment. Typically, patients tolerate over 150 pulses per session. Treatment pain can be minimized by a number of topical anesthetic creams, such as LM-X (lidocaine 4%) (Ferndale Laboratories, Ferndale, MI, USA). Occasionally, a thin, nontreated stripe between reticular footprints can be seen (Figure 7). This is easily corrected with subsequent treatment applying the crystal over the nontreated sites or proceeding with treatment using the crystal rotated 90 degrees from the original direction. In the past 8 years, we have observed very few patients in whom small rectangular spots of hypopigmentation at the lateral neck margins have persisted at the end of 2 years. This was preceded by epidermal desquamation.

With the newest progressive set of parameters, the incidence of acute side effects has been markedly reduced. Side effects include a mild burning sensation lasting less than 10 minutes noted in 45% and erythema, which typically lasts several hours to 3 days. Mild cheek swelling or edema occurs 25% of the time with full-face treatments, primarily after the initial treatment, and lasts from 24 to 72 hours. Short-term hyper- or hypopigmentation (< 2 months) has been noted in approximately 8 to 15% of sites treated.

Summary

IPL is a system in which a flashlamp is pulsed under computer control with the use of filters to remove the wavelengths below 515 nm emitted by the flashlamp. The peak emission is yellow, but the entire spectrum is 515 to 1,200 nm of this noncoherent light source. IPL has turned out to be more valuable than initially thought for facial telangiectasia, irregular pigmentation, textural skin smoothing, reduction in poikilodermatous changes, and hair removal. Excellent clinical results for small red telangiectasias are achieved by use of synchronized pulses with an initial short pulse of 2.4 to 3 milliseconds coupled with a second longer pulse duration of 4 to 8 milliseconds, with a progressive increase in duration and fluence based on increasing vessel size. Adverse effects include epidermal crusting, but proper technique and adherence to published parameters minimize this possibility.

References

1. Weiss RA, Goldman MP, Weiss MA. Treatment of poikiloderma of Civatte with an intense pulsed light source. Dermatol Surg 2000;26:823–7.
2. Bitter PH. Noninvasive rejuvenation of photodamaged skin using serial, full-face intense pulsed light treatments. Dermatol Surg 2000;26:835–42.

3. Goldberg DJ, Cutler KB. Nonablative treatment of rhytids with intense pulsed light. Lasers Surg Med 2000;26:196–200.
4. Raulin C, Schroeter CA, Weiss RA, et al. Treatment of port-wine stains with a noncoherent pulsed light source: a retrospective study. Arch Dermatol 1999;135:679–83.
5. Jay H, Borek C. Treatment of a venous-lake angioma with intense pulsed light [letter]. Lancet 1998;351:112.
6. Weiss RA, Weiss MA, Marwaha S, Harrington AC. Hair removal with a non-coherent filtered flashlamp intense pulsed light source. Lasers Surg Med 1999;24:128–32.
7. Raulin C, Schroeter C, Maushagen-Schnaas E. [Treatment possibilities with a high-energy pulsed light source (PhotoDerm VL)]. Hautarzt 1997;48:886–93.
8. Raulin C, Weiss RA, Schonermark MP. Treatment of essential telangiectasias with an intense pulsed light source (PhotoDerm VL). Dermatol Surg 1997;23:941–5.
9. Raulin C, Goldman MP, Weiss MA, Weiss RA. Treatment of adult port-wine stains using intense pulsed light therapy (PhotoDerm VL): brief initial clinical report [letter]. Dermatol Surg 1997;23:594–7.
10. Schroeter C, Wilder D, Reineke T, et al. Clinical significance of an intense, pulsed light source on leg telangiectasias of up to 1mm diameter. Eur J Dermatol 1997;7:38–42.
11. Sadick NS, Weiss RA, Shea CR, et al. Long-term photoepilation using a broad-spectrum intense pulsed light source. Arch Dermatol 2000;136:1336–40.
12. Weiss RA, Sadick NS. Epidermal cooling crystal collar device for improved results and reduced side effects on leg telangiectasias using intense pulsed light. Dermatol Surg 2000;26:1015–8.
13. Sommer A, Van MP, Neumann HA, Kessels AG. Red and blue telangiectasias. Differences in oxygenation? Dermatol Surg 1997;23:55–9.
14. Keijzer M, Jacques SL, Prahl SA, Welch AJ. Light distributions in artery tissue: Monte Carlo simulations for finite-diameter laser beams. Lasers Surg Med 1989;9:148–54.
15. Adrian RM. Treatment of leg telangiectasias using a long-pulse frequency-doubled neodymium:YAG laser at 532 nm. Dermatol Surg 1998;24:19–23.
16. Dierickx CC, Casparian JM, Venugopalan V, et al. Thermal relaxation of port-wine stain vessels probed in vivo: the need for 1–10 millisecond laser pulse treatment. J Invest Dermatol 1995;105:709–14.
17. Kimel S, Svaasand LO, Hammer-Wilson M, et al. Differential vascular response to laser photothermolysis. J Invest Dermatol 1994;103:693–700.
18. Goldman MP, Eckhouse S. Photothermal sclerosis of leg veins. ESC Medical Systems, LTD Photoderm VL Cooperative Study Group. Dermatol Surg 1996;22:323–30.
19. Green D. Photothermal sclerosis of leg veins [letter; comment]. Dermatol Surg 1997;23:303–5.
20. Zelickson B, Kist D. Pulsed dye laser and photoderm treatment stimulates production of type-I collagen and collagenase transcripts in papillary dermis fibroblasts [abstract]. Lasers Surg Med Suppl 2001;13:33.
21. Zelickson B, Kist D. Effect of pulse dye laser and intense pulsed light source on the dermal extracellular matrix remodeling [abstract]. Lasers Surg Med Suppl 2000;12:17.
22. Hernandez-Perez E, Ibiett EV. Gross and microscopic findings in patients submitted to nonablative full face resurfacing using intense pulsed light. Dermatol Surg 2002;28:651–5.
23. Prieto VG, Sadick NS, Lloreta J, et al. Effects of intense pulsed light on sun-damaged human skin, routine, and ultrastructural analysis. Lasers Surg Med 2002;30:82–5.
24. Negishi K, Wakamatsu S, Kushikata N, et al. Full-face photorejuvenation of photodamaged skin by intense pulsed light with integrated contact cooling. Lasers Surg Med 2002;30:298–305.
25. Negishi K, Tezuka Y, Kushikata N, Wakamatsu S. Photorejuvenation for Asian skin by intense pulsed light. Dermatol Surg 2001;27:627–32.
26. Huang YL, Liao YL, Lee SH, Hong HS. Intense pulsed light for the treatment of facial freckles in Asian skin. Dermatol Surg 2002;28:1007–12.
27. Kawada A, Shiraishi H, Asai M, et al. Clinical improvement of solar lentigines and ephelides with an intense pulsed light source. Dermatol Surg 2002;28:504–8.
28. Weiss RA, Weiss MA, Beasley KL. Rejuvenation of photoaged skin: 5 year results with intense pulsed light of the face, neck, and chest. Dermatol Surg 2002;28:1115–9.
29. Beasley KL, Weiss RA, Weiss MA. New parameters for intense pulsed light rejuvenation with a thermoelectrically chilled crystal delivery system. Cosmet Dermatol 2002;15:14–6.
30. Bjerring P, Christiansen K, Trolius A, Dierickx C. Facial photorejuvenation using two different intense pulsed light (IPL) wavelength bands. Lasers Surg Med 2004;34:120–6.
31. Ruiz-Rodriguez R, San-Sanchez T, Cordoba S. Photodynamic photorejuvenation. Dermatol Surg 2002;28:742–4.
32. Fritsch C, Goerz G, Ruzicka T. Photodynamic therapy in dermatology. Arch Dermatol 1998;134:207–14.
33. Kalla K, Merk H, Mukhtar H. Photodynamic therapy in dermatology. J Am Acad Dermatol 2000;42:389–413.
34. HongcharuW, Taylor CR, Chang Y, et al. Topical ALA-photodynamic therapy for the treatment of acne vulgaris. J Invest Dermatol 2000;115:183–92.
35. Fowler JF, Zax RH. Aminolevulinc acid hydrochloride with photodynamic therapy: efficacy outcomes and recurrence 4 years after treatment. Cutis 2002;69(6 Suppl):2–7.
36. Alexiades-Armenakas M, Kauvar ANB, Bernstein LJ, et al. Laser-assisted photodynamic therapy of actinic keratoses. Lasers Surg Med Suppl 2002;14:24.
37. Gold MH. The evolving role of aminolevulinic acid hydrochloride with photodynamic therapy in photoaging. Cutis 2002;69(6 Suppl):8–13.

Commentary

Intense pulsed light (IPL) is a great example of technology that was ahead of its time. This article details the challenges of perfecting methods of treatment to optimize this technology since its introduction in the early- to mid-1990s. My previous training in the treatment of photoaging lesions centered on the use of more traditional methods, such as chemical peeling and pulsed dye lasers.

Over the past 2 years, I have come to appreciate the utility of IPL for treating these lesions. Current strategies, as outlined in the article, including double pulsing with short delays and thin gel technique, achieve excellent, reproducible clearance of lentigines and telangiectasia with minimal downtime. IPL has become my treatment of choice for patients with mild to moderate photoaging.

GIRISH MUNAVALLI, MD
Hunt Valley, MD